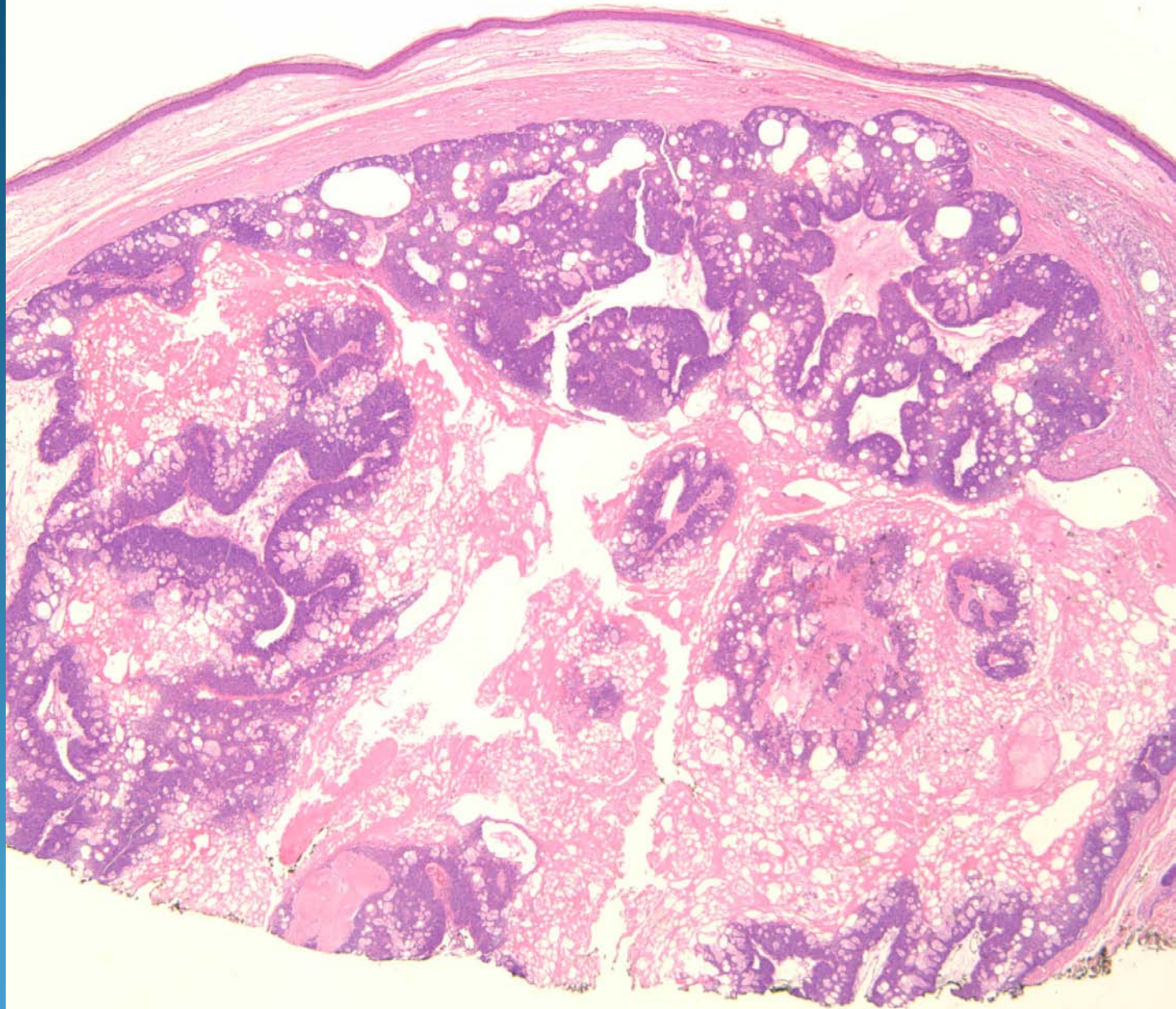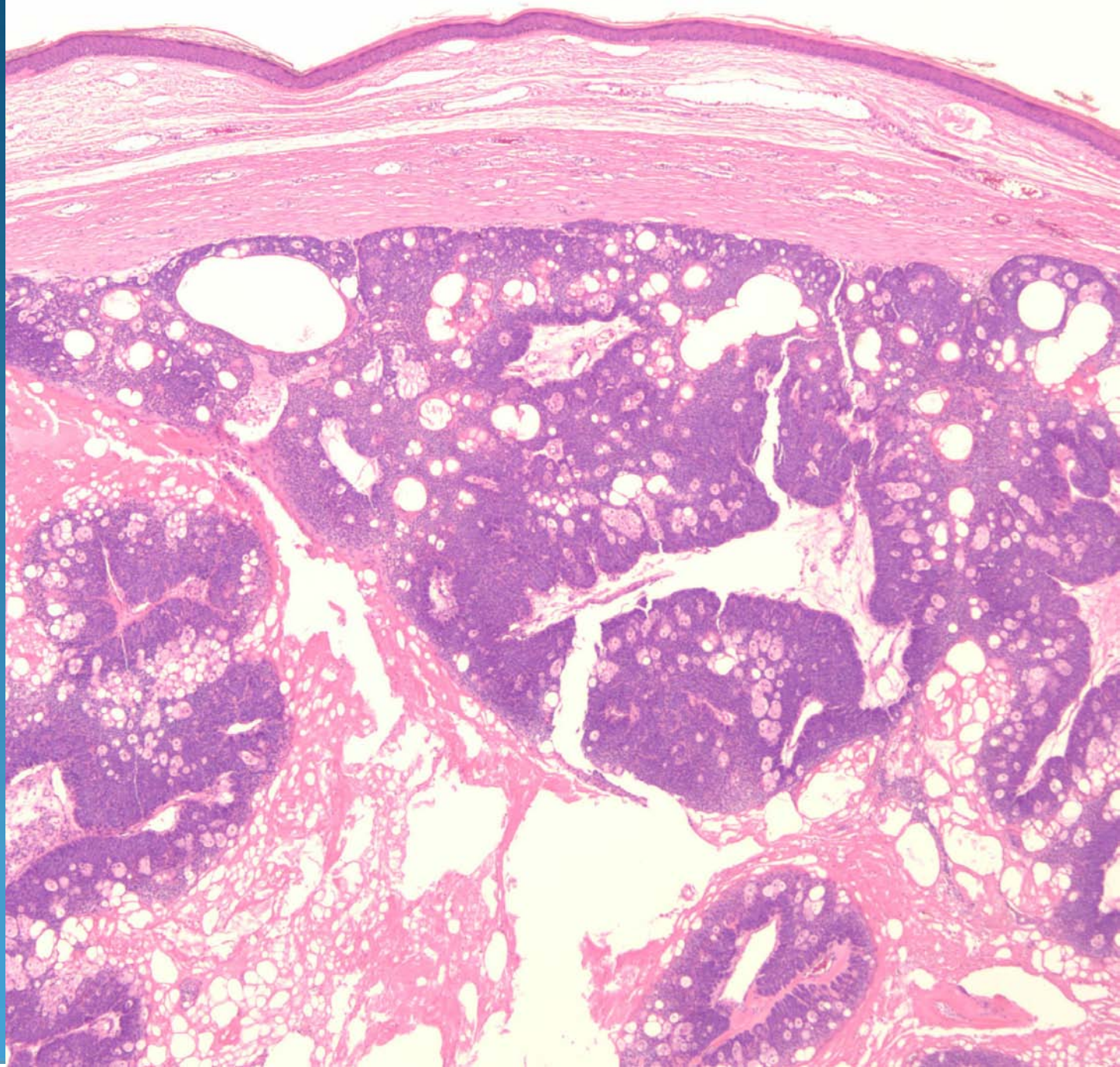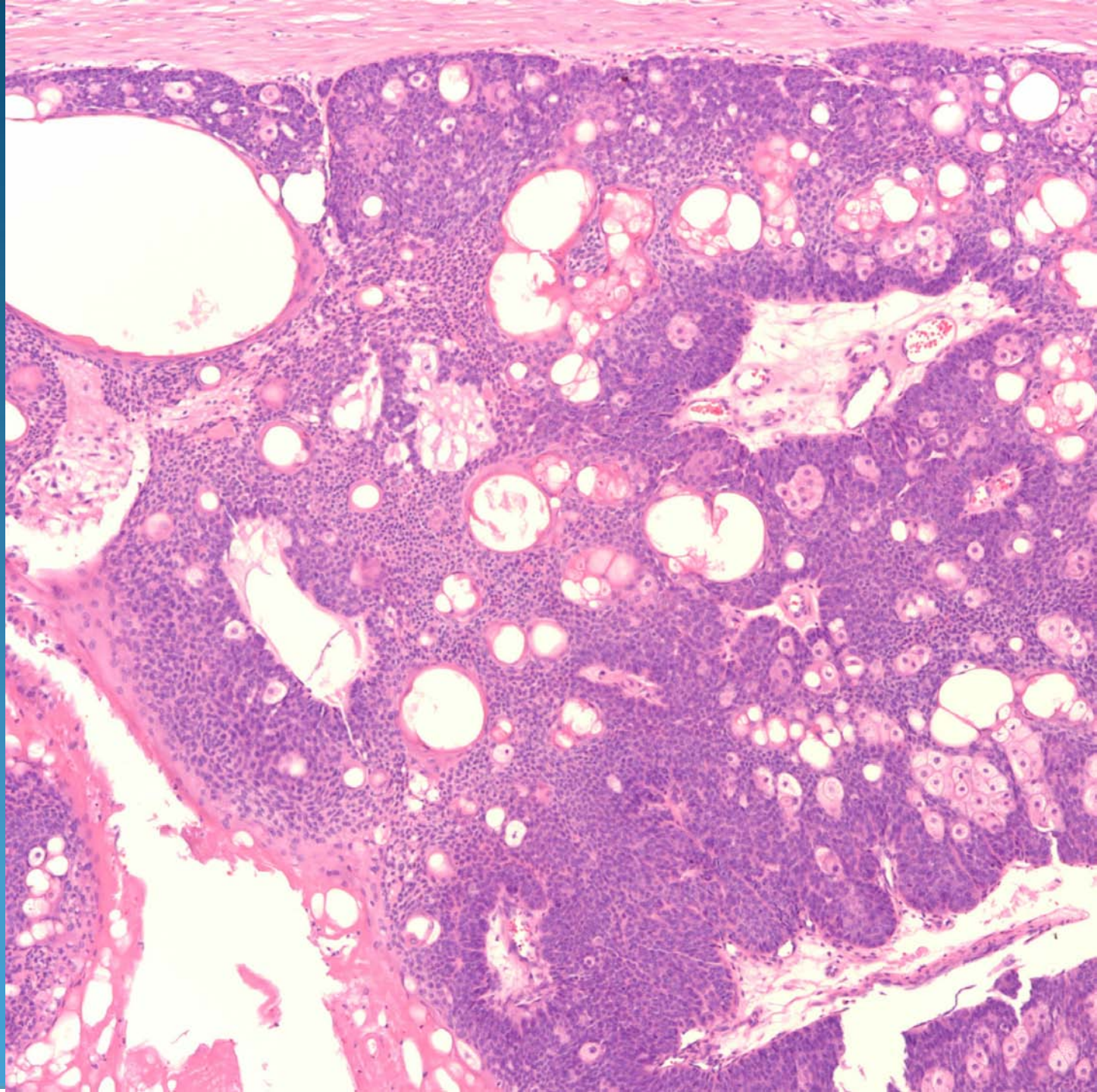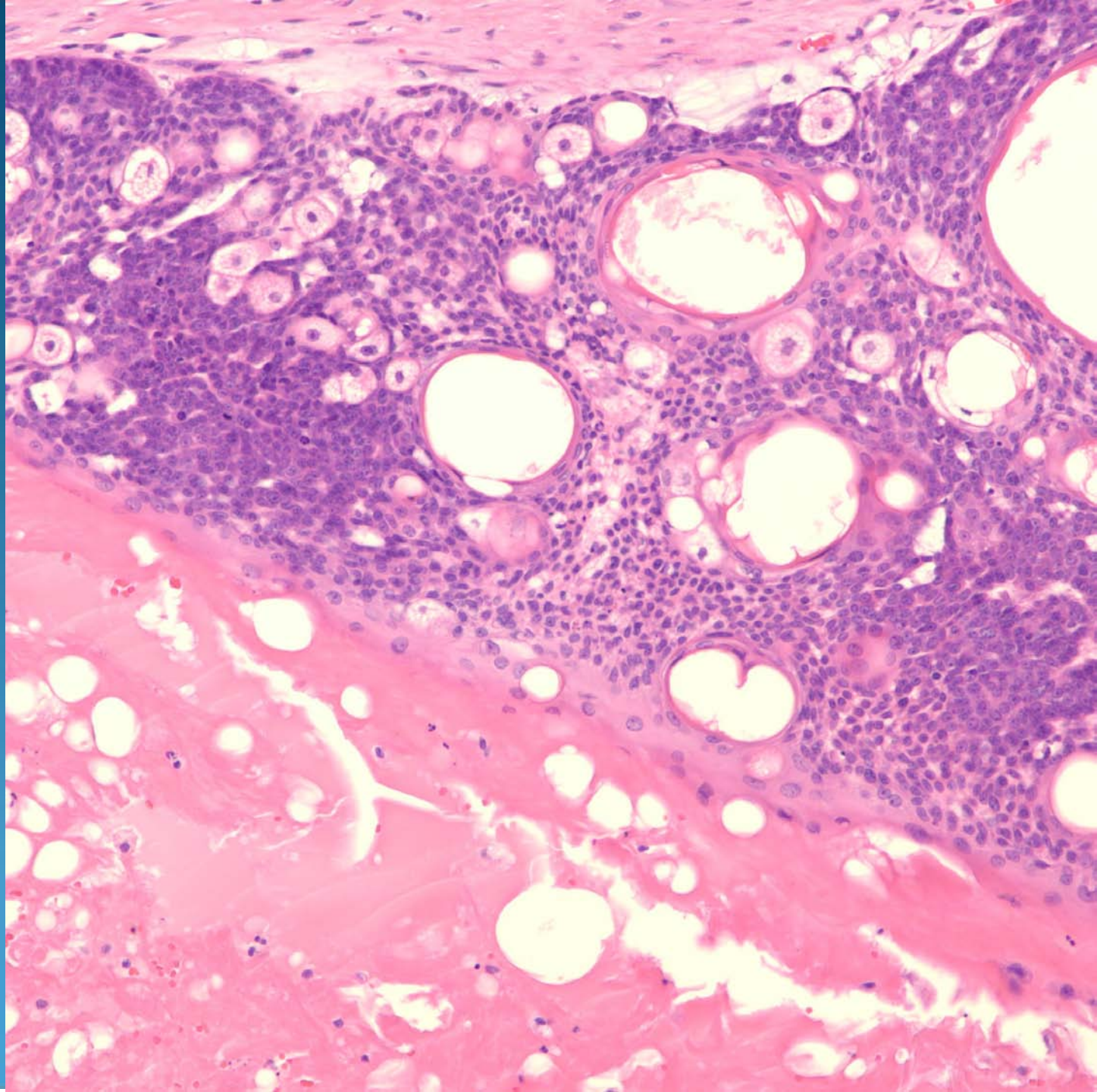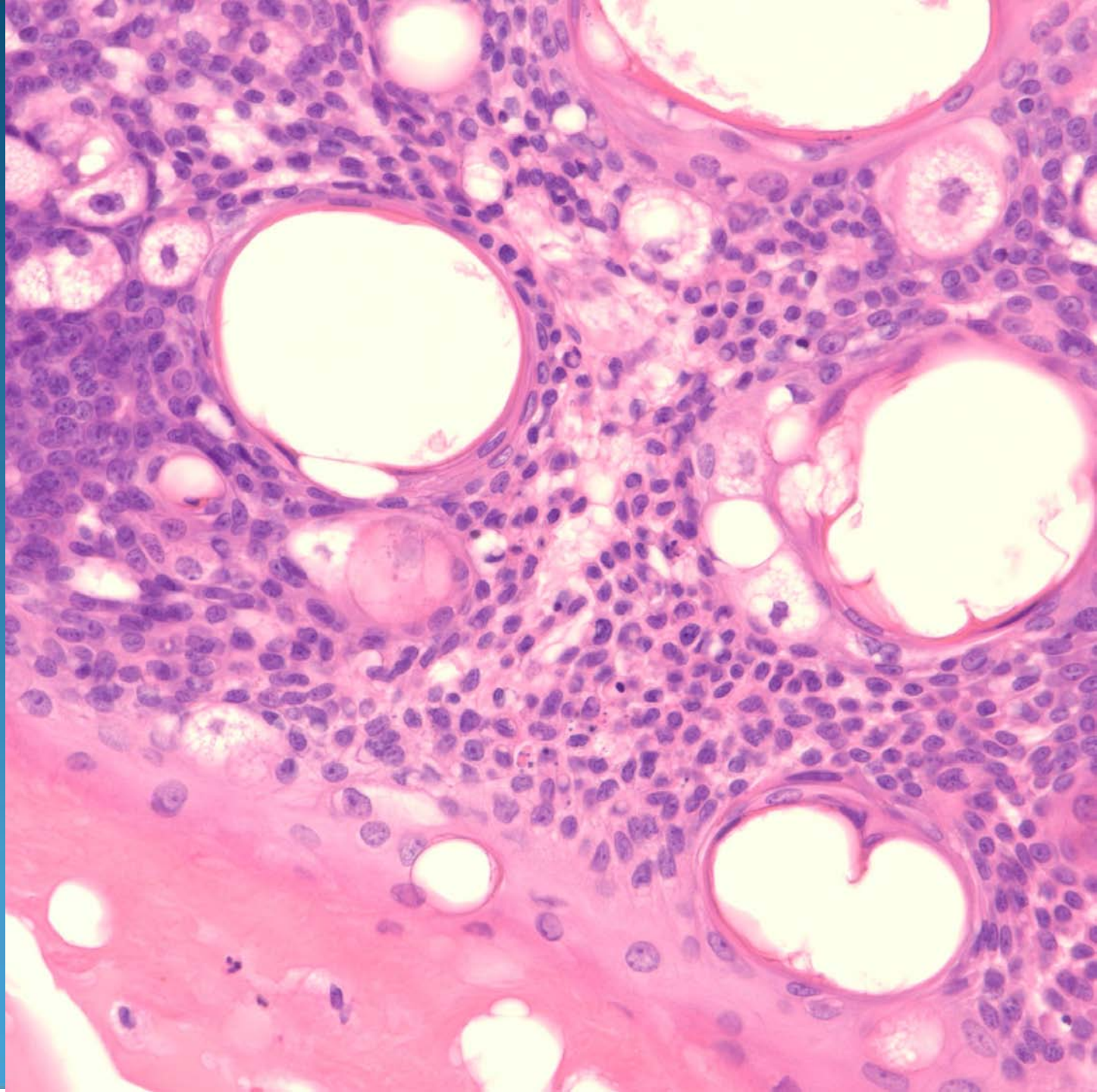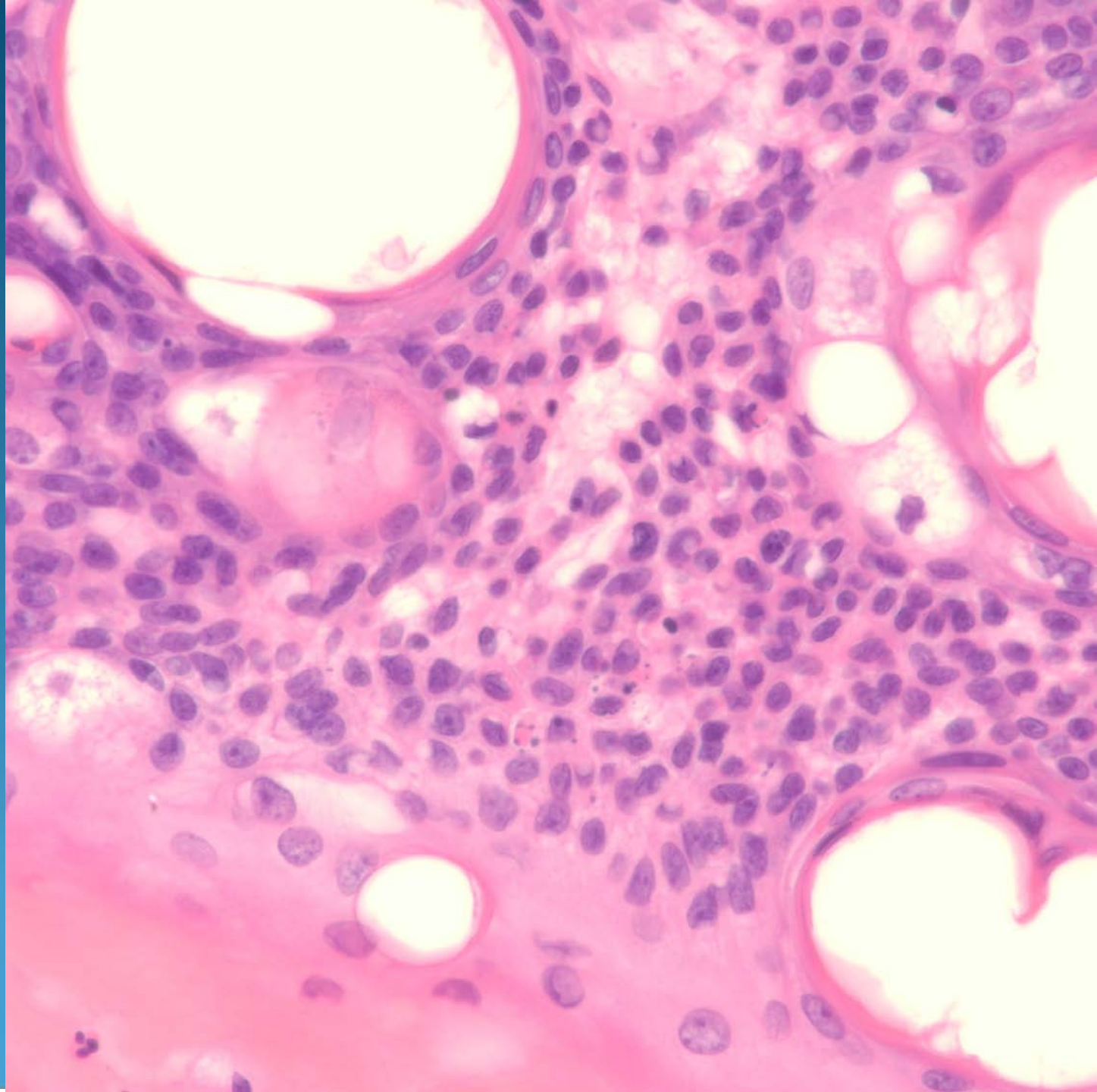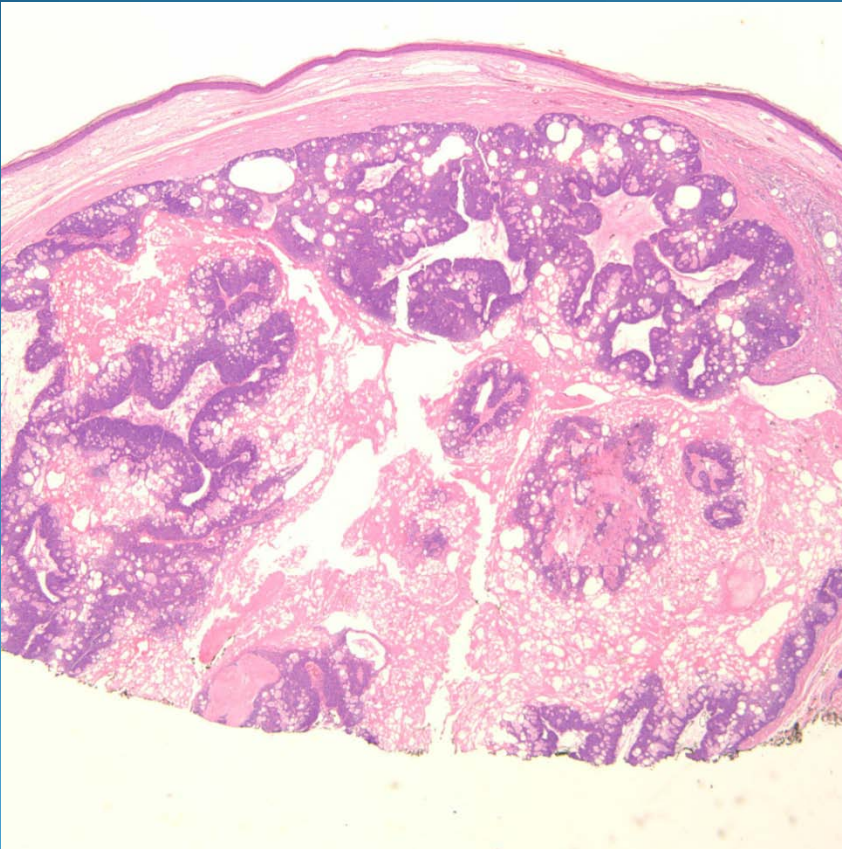


Sebaceoma

Pearls



- Circumscribed dermal nodule of basaloid cells with sebocytes in varying stages of maturation
- Large areas of holocrine secretion
- Lacking peripheral palisading